

# ADOLESCENTS' DRAWINGS OF THEIR CARDIAC ABNORMALITY

QiFeng Wang, Samuel Menahem, Margaret Hay & David Clarke  
School of Psychology and Psychiatry, Monash University, Melbourne

# Overview

- Background
- Aims
- Methods
- Results
- Conclusions

# Background

- Increasing surviving population of adolescents with congenital heart disease.
- Patients previously shown to have a poor knowledge.
- Melbourne children and adolescents with innocent murmurs or small VSDs had poor knowledge of their lesions <sup>1,2</sup>.

1. Advani, Menahem, & Wilkinson. (2002)

2. Shau Wan, Menahem, 2008



**MONASH** University  
Medicine, Nursing and Health Sciences



Helping Young People Grow!

Centre for Developmental Psychiatry & Psychology

# Aims

- To assess adolescents' anatomical knowledge of their cardiac condition.
- To determine if this knowledge their cardiac condition was reflected in their drawings of
- To determine if their knowledge influenced their quality of life.

# Method

- Recruitment:
  - Patients aged 12-20 years old with heart disease
  - Exclusion criteria:
    - intellectual disabilities
    - other chronic disease
    - non-English speaking
- Study setting:
  - MMC outpatient/private rooms
- Participants were asked to draw a diagram to illustrate their cardiac problem in addition to completing a detailed questionnaire. (67 completed at home)

# Participants information

- N=120
- Male 65 (54%)
- Mean age 16 yrs SD 6
- 19 (16%) had family history of CHD
- 21 (17%) had previous cyanotic CHD.
- 98% NYHA class I (2 patients in class III)

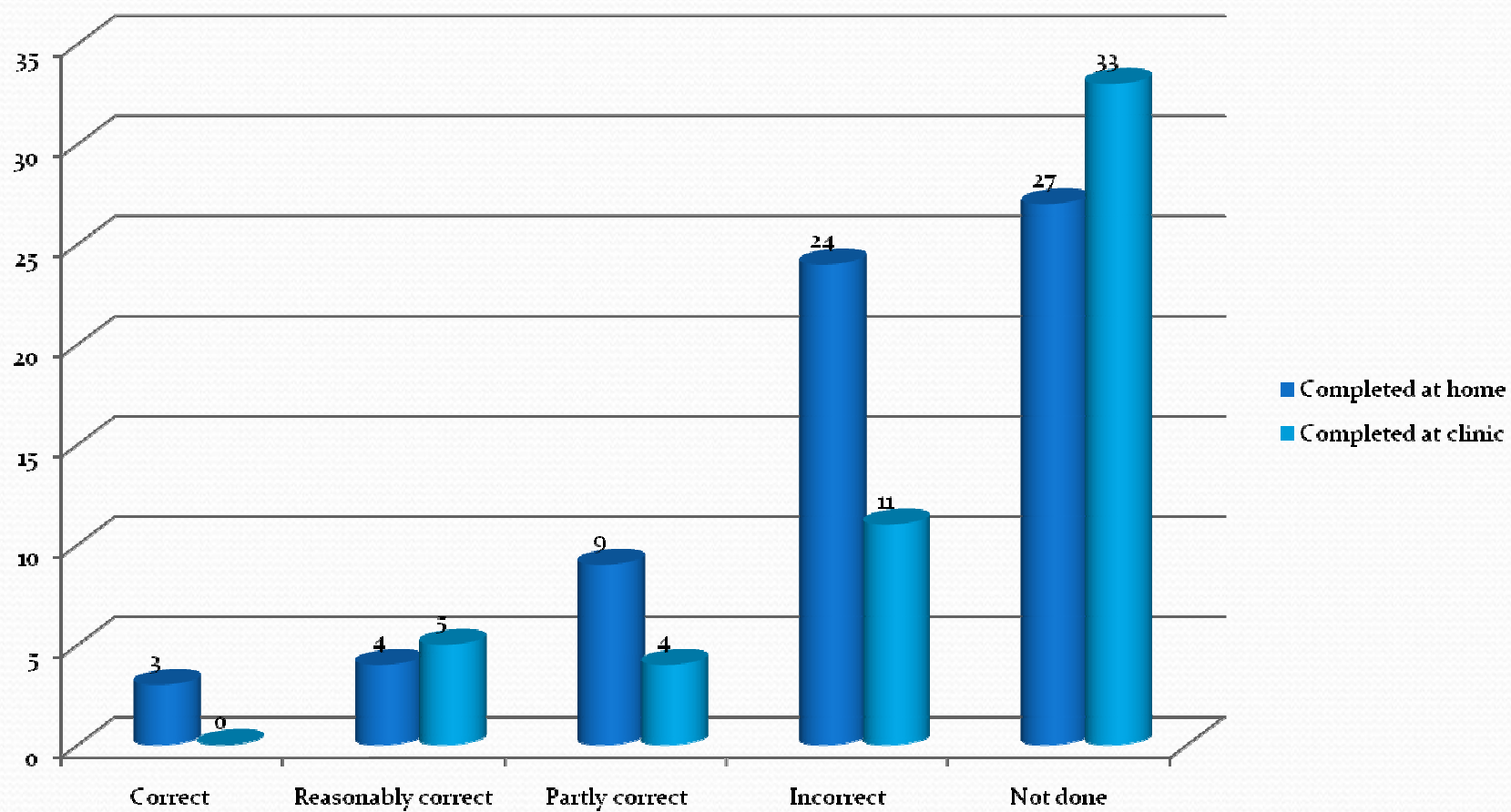
# Primary medical diagnosis

- Tetralogy of Fallot (8%)
- Aortic valve stenosis (24%)
- Pulmonary valve stenosis (9%)
- Transposition of Great Arteries (5%)
- Coarctation of aorta (9%)
- VSD, ASD, AVSD (19%)
- Other valvular disease (include Marfan syndrome) (15%)
- Other complex CHDs (3%)
- Acquired heart disease and/or arrhythmias (8%)

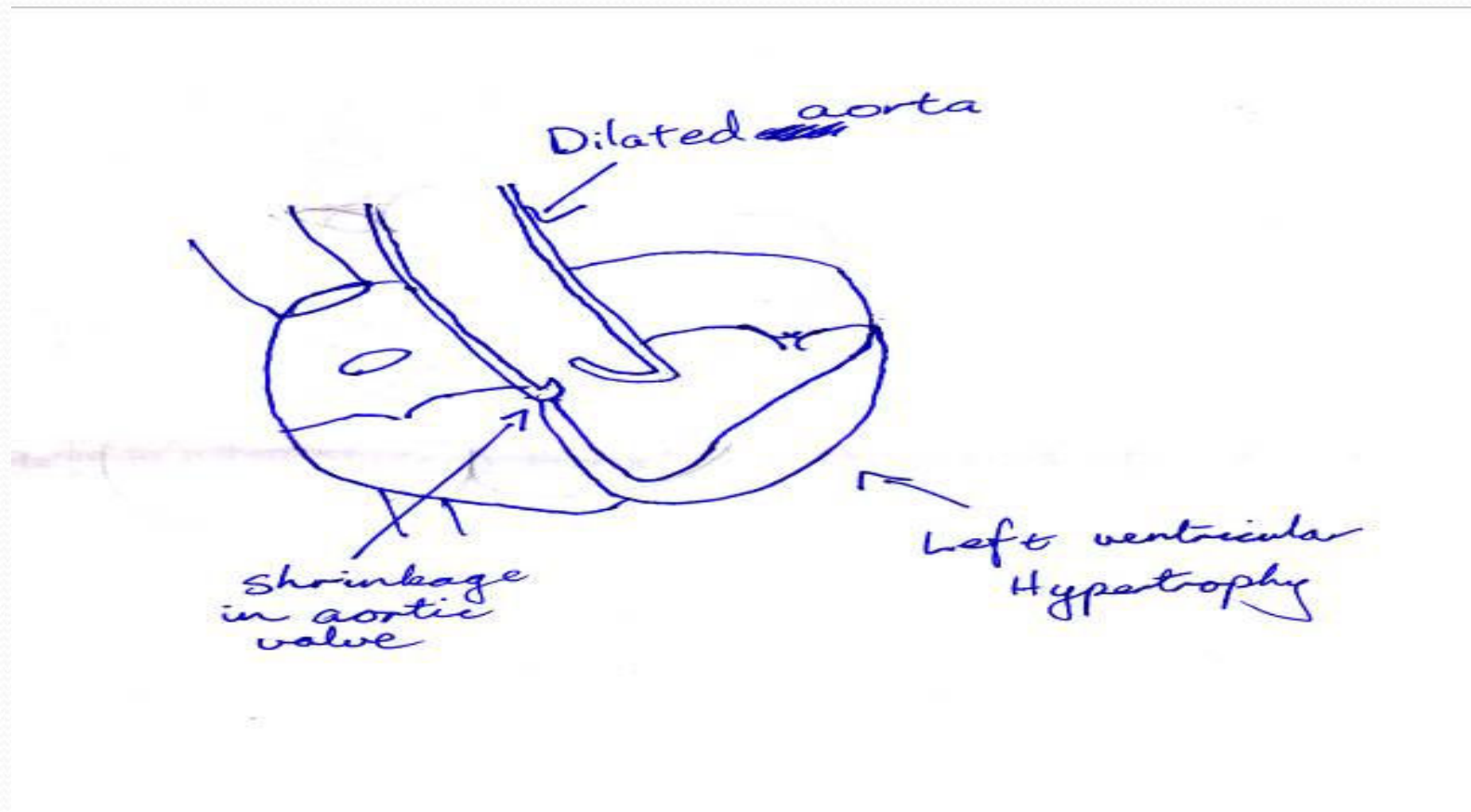
# Results

- Half of the participants were not able to complete the task of drawing their heart abnormality.
- Only 3 patients (all completed at home) drew a correct diagram
- 9 (8%) patients (4 at home) drew a reasonably correct diagram
- 13 (11%) patients (9 at home) partially correct diagrams
- 35 (29%) patients (24 at home) incorrect diagrams

Figure 1 *Results of patients' drawing*



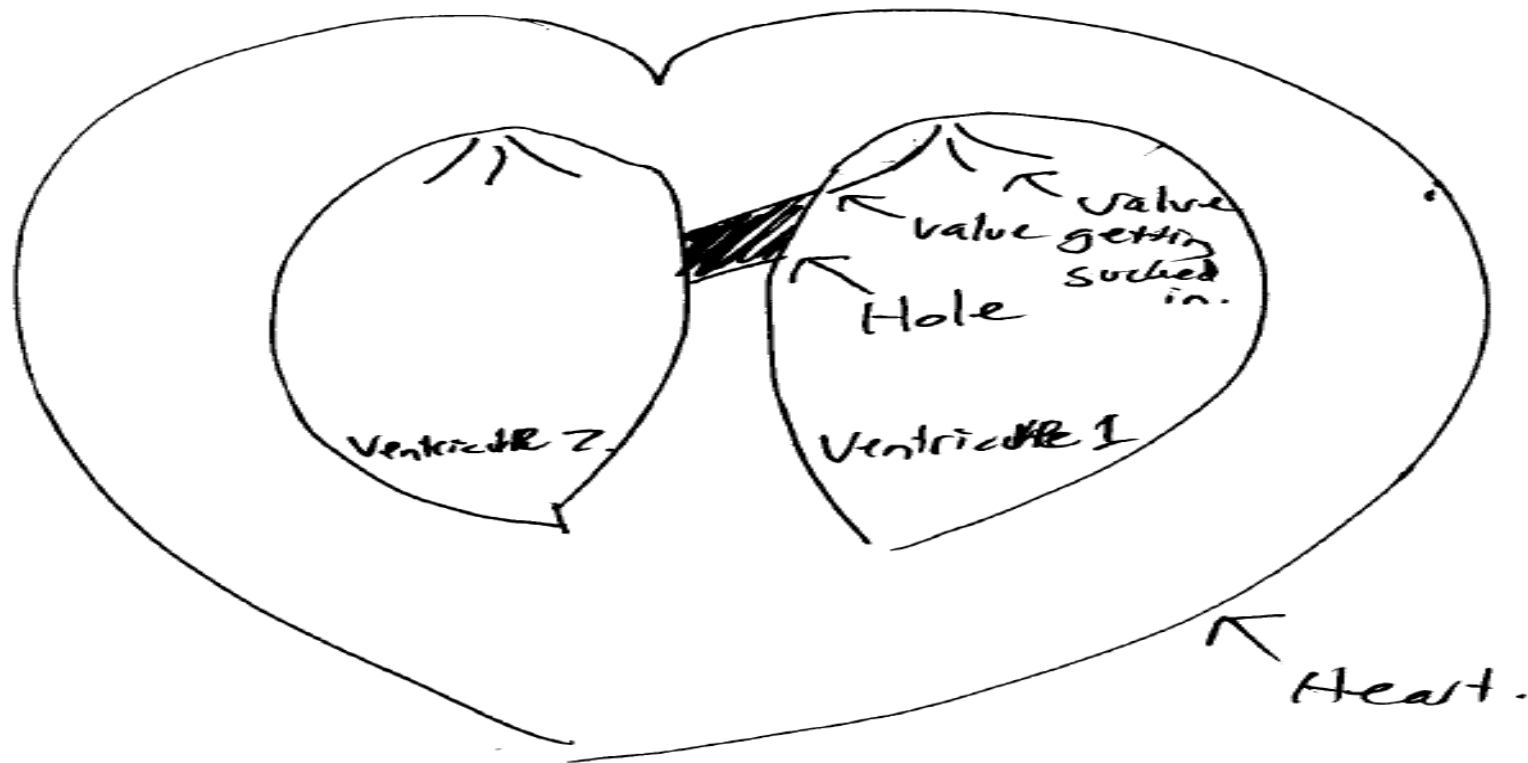
# Examples of drawings



- Patient ID 94: (age 17), done at home.
- **Diagnosis:** AVS, dilated LV, LV hypertrophy



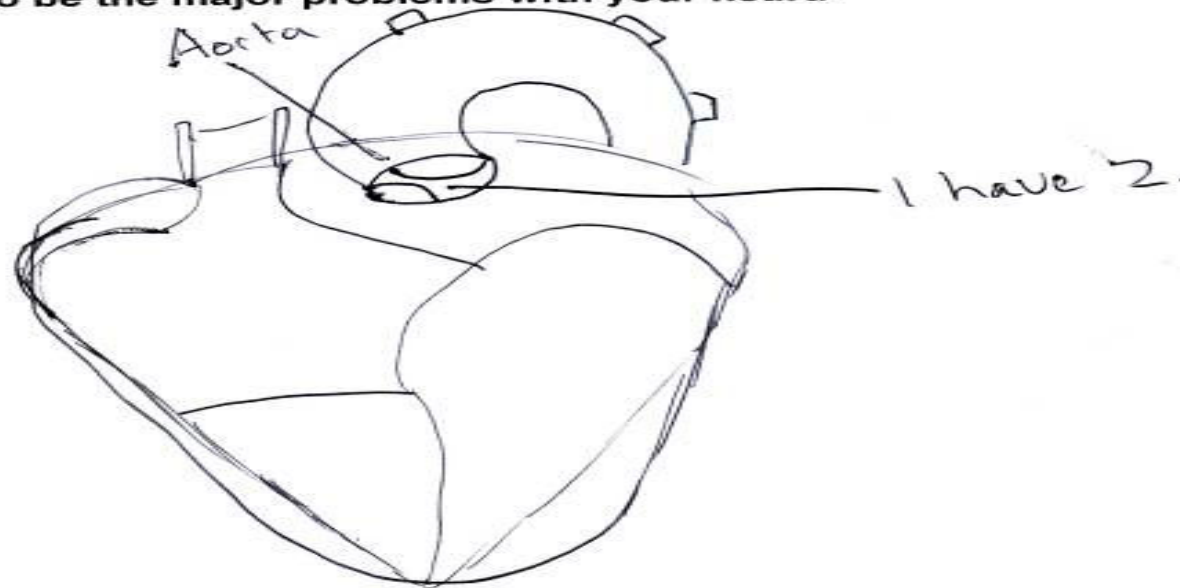
# Examples of drawings



- Patient ID 104: (age 15), done at home
- **Diagnosis:** VSD, AV prolapse

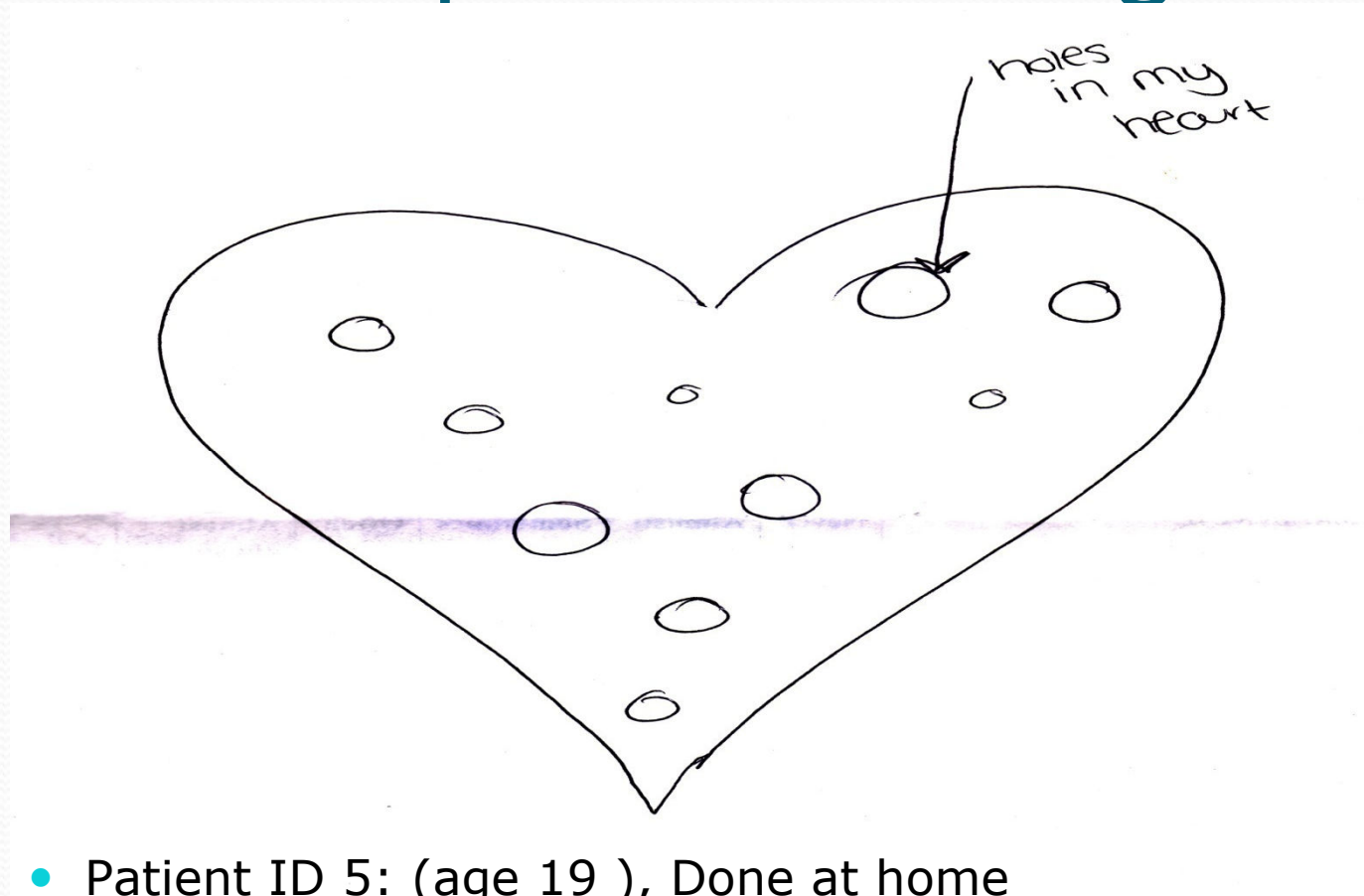
# Examples of drawings

On this page, Please draw diagram of your heart and indicate what you consider to be the major problems with your heart.



- Patient ID 38: (age 15), done at home
- **Diagnosis:** Aortic stenosis, bicuspid aortic valve

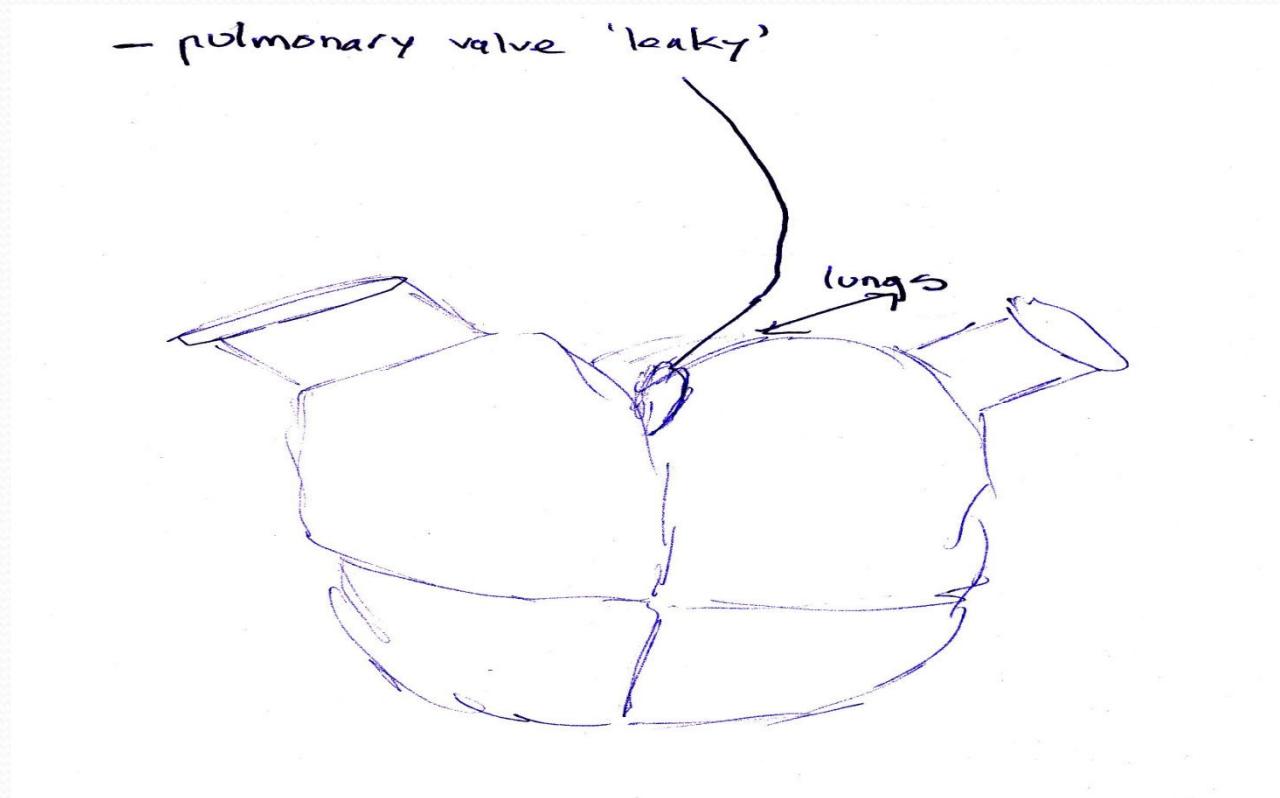
# Examples of drawings



- Patient ID 5: (age 19 ), Done at home
- **Diagnosis:** VSDs, mild PVS



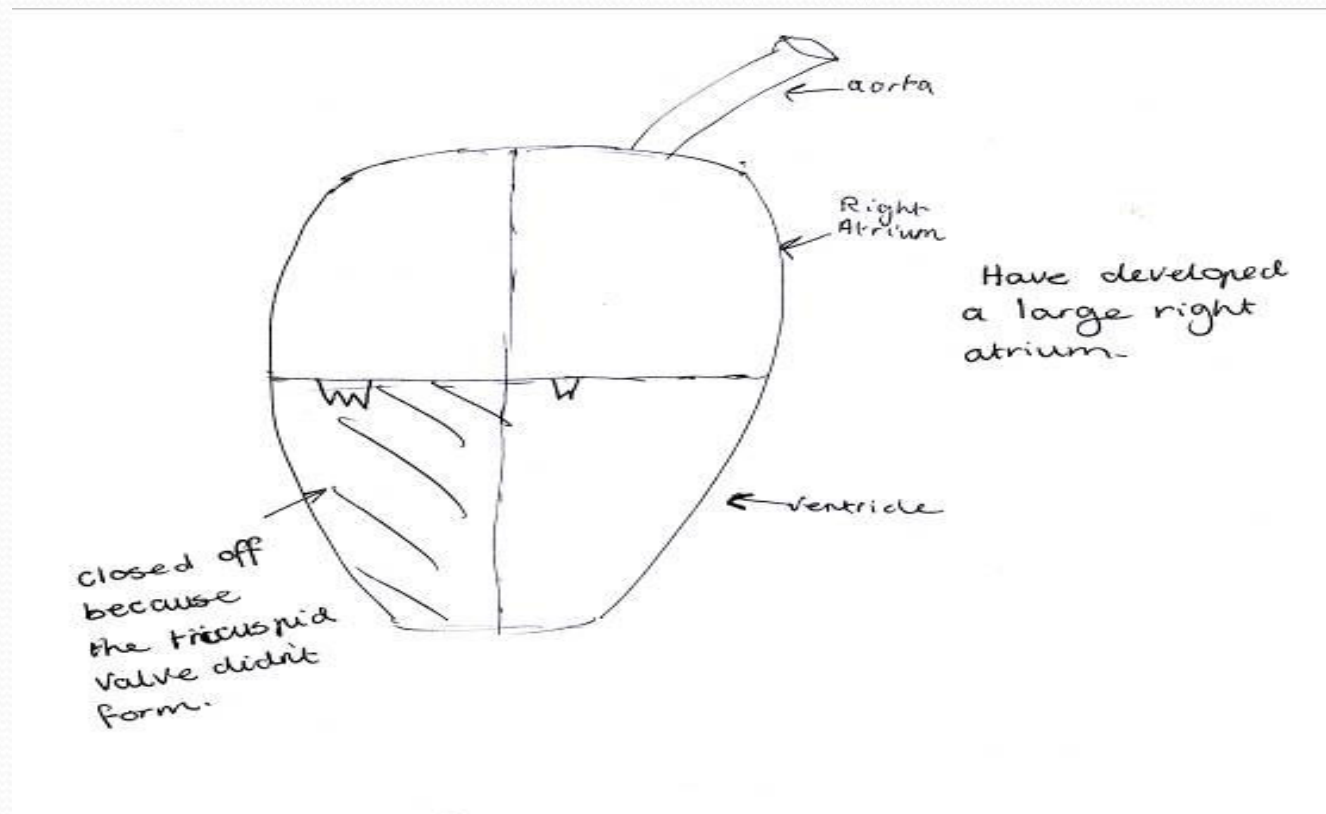
# Examples of drawings



- Patient ID 58: (age 17) , done at clinic
- **Diagnosis:** TOF, residual PVS, PI

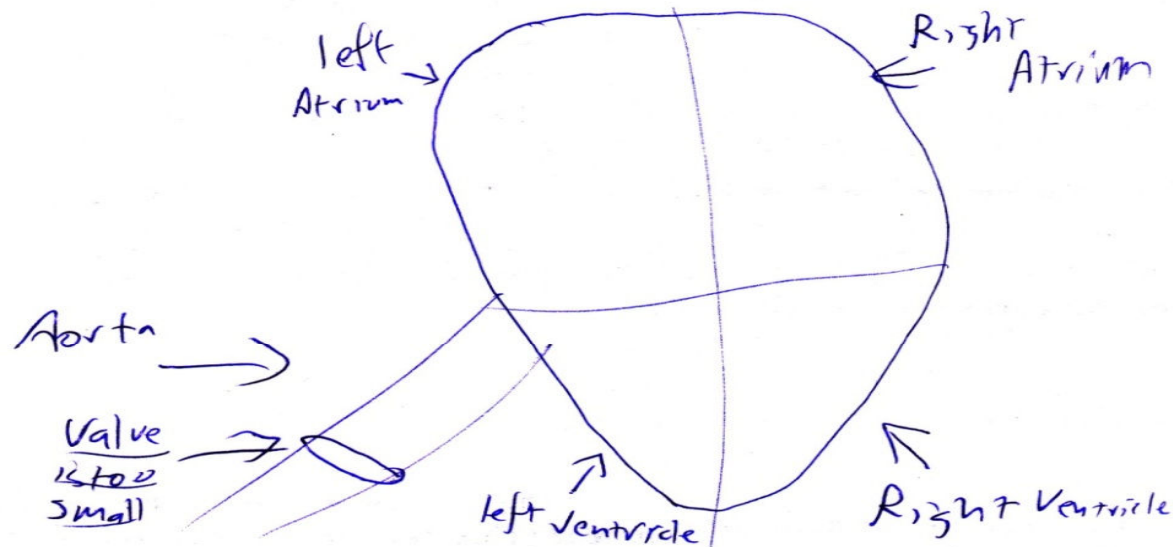


# Examples of drawings



- Patient ID 25: (age 20 ), done at clinic
- **Diagnosis:** tricuspid atresia, hypoplastic RV, post Fontan

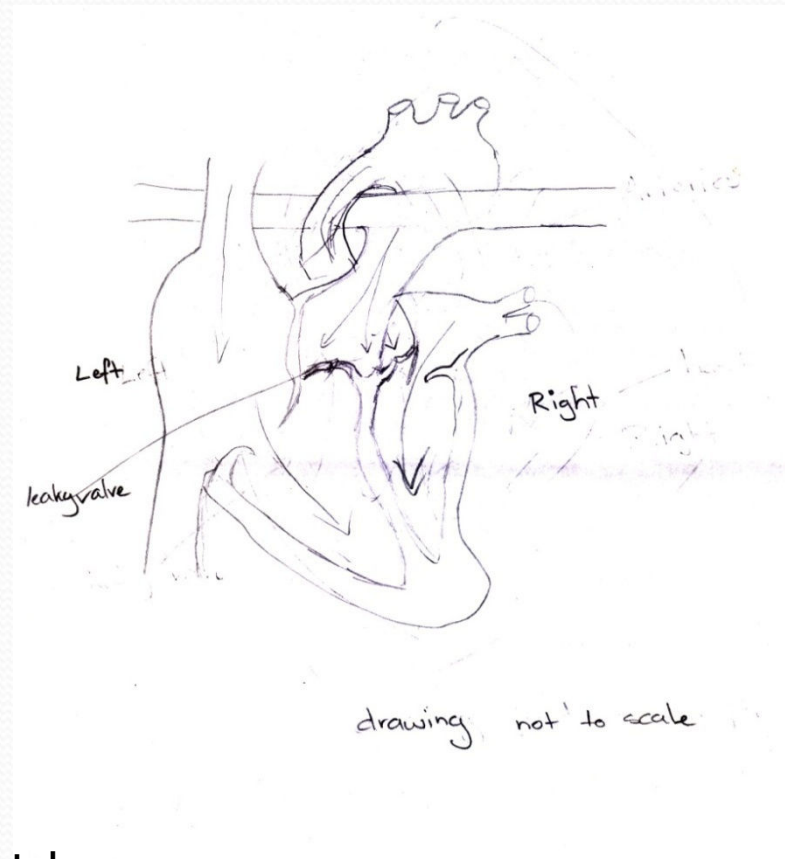
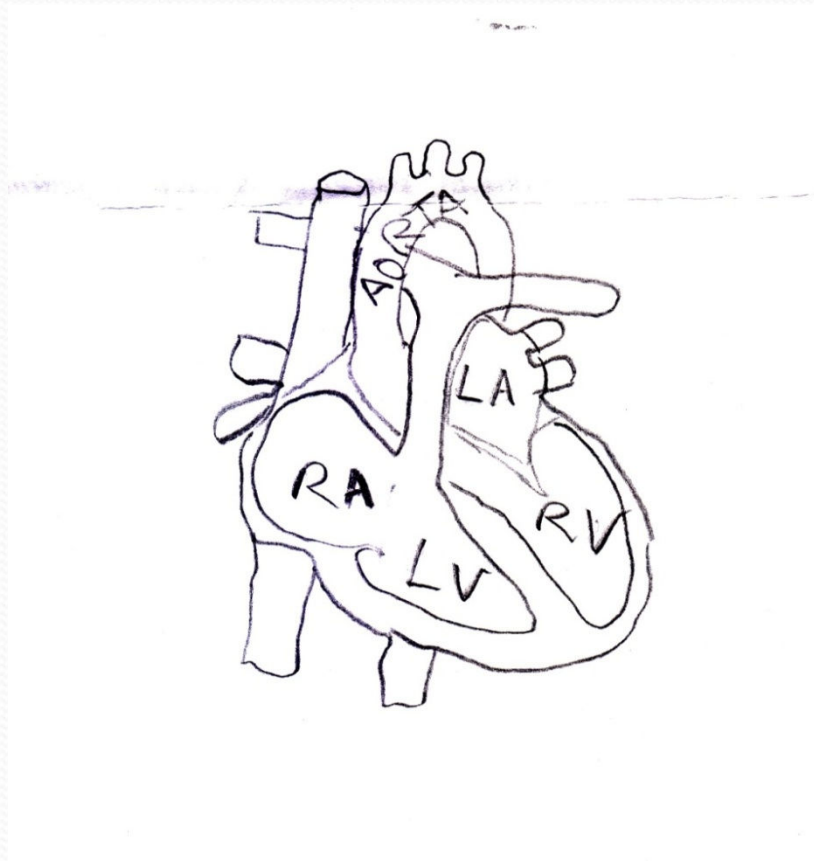
# Examples of drawings



- Patient ID 2: (age 16), done at clinic
- **Diagnosis:** Bicuspid AV, AS, AI



# Examples of drawings



Done at home

# Conclusions

- Adolescents had a poor anatomical knowledge of their cardiac abnormalities
- Further educational programs need be developed to improve their knowledge
- Such improved knowledge may impact on patients' health related quality of life

*THANK YOU!*



**MONASH** University  
Medicine, Nursing and Health Sciences